

# *Rapid identification of bilateral adrenal and pituitary haemorrhages induced by Russell's viper envenomation results in positive patient outcome*

Article

Published Version

Creative Commons: Attribution 4.0 (CC-BY)

Open Access

Senthilkumaran, Subramanian, Almeida, José R., Williams, Jarred, Williams, Harry F., Thirumalaikolundusubramanian, Ponniah, Patel, Ketan and Vaiyapuri, Sakthi ORCID

logoORCID: <https://orcid.org/0000-0002-6006-6517> (2023)

Rapid identification of bilateral adrenal and pituitary haemorrhages induced by Russell's viper envenomation results in positive patient outcome. *Toxicon*, 225. 107068. ISSN 0041-0101 doi:

<https://doi.org/10.1016/j.toxicon.2023.107068> Available at <https://centaur.reading.ac.uk/110939/>

It is advisable to refer to the publisher's version if you intend to cite from the work. See [Guidance on citing](#).

To link to this article DOI: <http://dx.doi.org/10.1016/j.toxicon.2023.107068>

Publisher: Elsevier


copyright holders. Terms and conditions for use of this material are defined in the [End User Agreement](#).

[www.reading.ac.uk/centaur](http://www.reading.ac.uk/centaur)

## **CentAUR**

Central Archive at the University of Reading

Reading's research outputs online



## Case report

# Rapid identification of bilateral adrenal and pituitary haemorrhages induced by Russell's viper envenomation results in positive patient outcome

Subramanian Senthilkumaran<sup>a,1</sup>, José R. Almeida<sup>b,1</sup>, Jarred Williams<sup>b,1</sup>, Harry F. Williams<sup>c</sup>, Ponniah Thirumalaikolundusubramanian<sup>d</sup>, Ketan Patel<sup>e</sup>, Sakthivel Vaiyapuri<sup>b,\*</sup>

<sup>a</sup> Manian Medical Centre, Erode, 638001, Tamil Nadu, India

<sup>b</sup> School of Pharmacy, University of Reading, Reading, RG6 6UB, UK

<sup>c</sup> Toxiven Biotech Private Limited, Coimbatore, 641042, Tamil Nadu, India

<sup>d</sup> The Tamil Nadu Dr M.G.R Medical University, Chennai, 600032, Tamil Nadu, India

<sup>e</sup> School of Biological Sciences, University of Reading, Reading, RG6 6UB, UK

## ARTICLE INFO

Handling Editor: Denise Tambourgi

## Keywords:

Acute haemorrhage  
Adrenal haemorrhage  
Dexamethasone  
Russell's viper  
Snakebite envenomation  
Pituitary haemorrhage

## ABSTRACT

The clinical management of snakebite envenomation (SBE) is challenging in many tropical and subtropical regions of developing countries due to the complex clinical manifestations and inadequate medical infrastructure. Some venomous snakes, such as the Indian Russell's viper (*Daboia russelii*) cause a wide range of rare complications in addition to their classical envenomation effects. In general, these uncommon complications are often misdiagnosed or not treated promptly due to a lack of awareness about these conditions. Thus, it is critical to report such complications to draw the attention of the healthcare and research communities to improve the clinical management and scientific research of SBE, respectively. Here, we report bilateral adrenal and pituitary haemorrhages in an SBE patient following a bite by Russell's viper in India. The initial symptoms included gum bleeding, swelling, axillary lymphadenopathy and clotting abnormalities. Despite the administration of antivenom, the patient presented palpitation, nausea, and abdominal pain, which were not recovered by combinational therapy with epinephrine and dexamethasone. Further infusion of antivenom did not address these issues and the patient displayed persistent hypotension, hypoglycaemia and hyperkalaemia suggesting an adrenal crisis. Inadequate secretion of corticosteroids was confirmed by laboratory tests, and imaging investigations revealed haemorrhages in both the adrenal and pituitary glands. The patient made a full recovery after treatment with hydrocortisone and thyroxine. This report adds to the growing evidence of rare complications induced by Russell's viper envenomations and it provides relevant guidance to diagnose and treat such complications in SBE victims.

## 1. Introduction

India is a major hotspot for snakebite envenomation (SBE) due to its large, rural agricultural communities (Longbottom et al., 2018). Poor outcomes are often observed in SBE victims in India due to the delay in seeking prompt care and inadequate healthcare infrastructure in rural settings (Williams et al., 2017; Vaiyapuri et al., 2023). Hence, SBE causes high rates of mortality, and morbidity, and a significant socio-economic burden on rural farming communities (Arnold, 2020; Suraweera et al., 2020). Epidemiological studies have identified Russell's

viper (*Daboia russelii*) as being the main perpetrator responsible for most bites (Vaiyapuri et al., 2013; Samuel et al., 2020). The clinical manifestations of Russell's viper envenomations display significant variations (Thorpe et al., 2007; Adhikari et al., 2019), while most patients manifest typical features, predominantly composed of local tissue damage, coagulopathies, nephrotoxicity and neurotoxicity, other victims also present various rare pathological complications such as Wunderlich syndrome (spontaneous non-traumatic renal haemorrhage) (Senthilkumaran et al., 2022a), priapism (prolonged penile erection) (Senthilkumaran et al., 2021b), salivary calculus development in the salivary

\* Corresponding author.

E-mail address: [s.vaiyapuri@reading.ac.uk](mailto:s.vaiyapuri@reading.ac.uk) (S. Vaiyapuri).

<sup>1</sup> These authors contributed equally to this study.

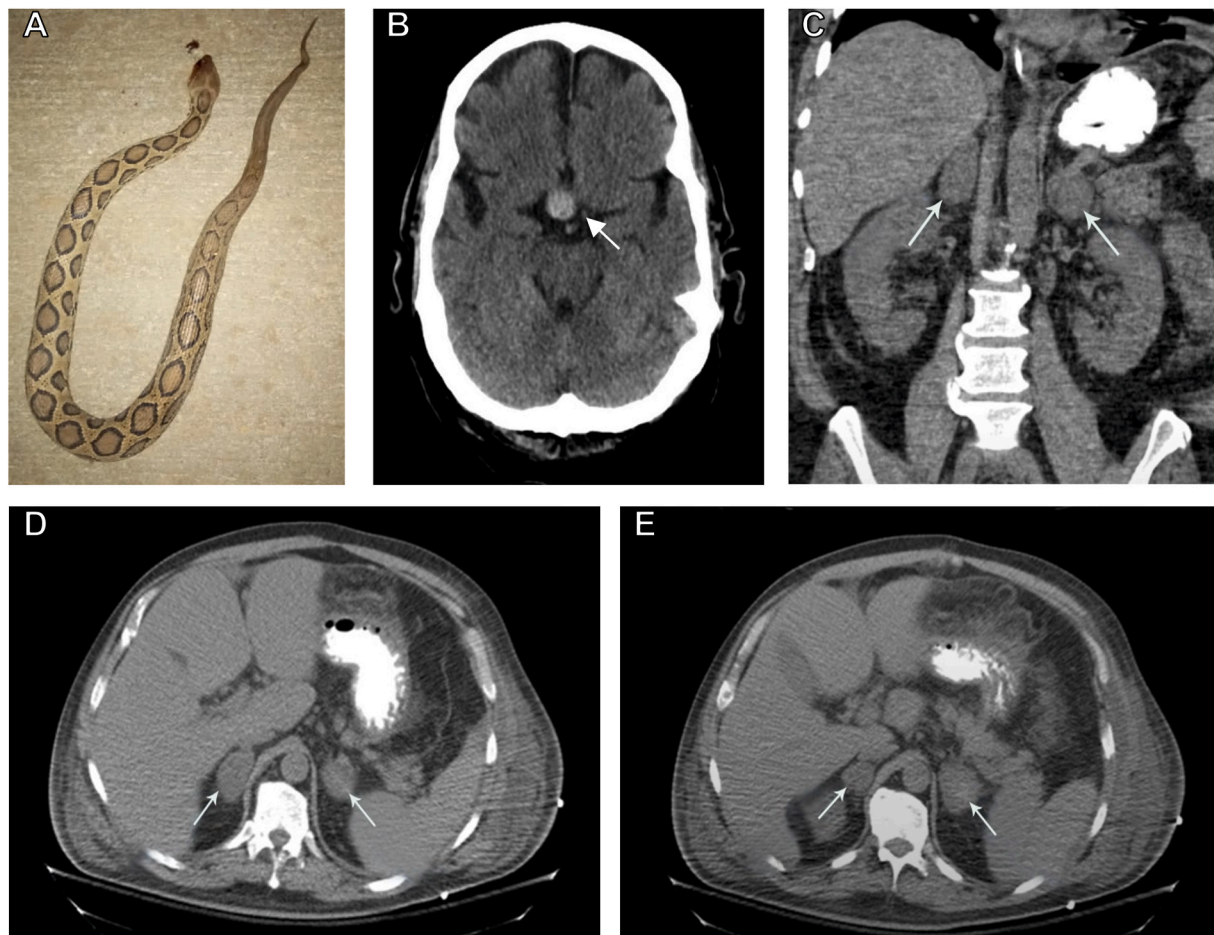
glands (Arathisenthil et al., 2022) and splenic rupture (Senthilkumaran et al., 2021a). A better understanding and broader knowledge surrounding the clinical manifestations of SBE in patients is crucial for medical practitioners to identify such rare complications and mitigate unfavourable outcomes. These data will also allow researchers to initiate novel research lines focused on molecular, biochemical, and epidemiological aspects relating to these poorly understood complications. In recent years, our research group has been making efforts to shed light on these underexplored effects that may contribute to the mortality and morbidity of SBE victims (Senthilkumaran et al., 2021a, 2021b, 2022b; Arathisenthil et al., 2022). Consistent with this aim, the present case demonstrates that Russell's viper envenomation can induce simultaneous haemorrhage into the adrenal and pituitary glands.

Disturbances in haemostasis and bleeding from damaged vessels are well documented following the viperid envenomations (Larréché et al., 2021). Skin, gums, nose, and urinary tract are some of the main bleeding sites (Lakhotia et al., 2014), but other underrepresented regions such as the suprarenal (Senthilkumaran et al., 2018) and pituitary (Thein and Byard, 2019) have also been described. Adrenal haemorrhage is an infrequent and acute clinical decompensation of multiple causes recognised by bleeding into endocrine organs (adrenal glands) located on top of each kidney (Simon and Palese, 2009). Historically, it has been classified according to the number of glands affected (unilateral or bilateral) and its aetiology (traumatic or non-traumatic) (Sharrack et al., 2020). This bleeding manifestation is particularly diverse and non-specific in terms of symptomology and can potentially be fatal

(Kolinioti et al., 2018). Similarly, pituitary haemorrhage is a highly variable endocrine emergency with a broad spectrum of signs and symptoms related to different aetiologies (Kim et al., 2009). Bleeding in adrenal and pituitary glands has been associated with SBE in isolation, including in India (Bhattacharya et al., 2020). In this article, we report a case whereby simultaneous bilateral adrenal and pituitary haemorrhages were present in the same patient following Russell's viper envenomation. We herein share our experience, detailing aspects of the diagnosis and treatment, which will be useful in the management of patients presenting similar clinical manifestations following SBE.

## 2. Case report

A 42-year-old, male farmer was bitten by a snake on his right index finger while working in the field, and the snake was later identified as Russell's viper (Fig. 1A) by a trained herpetologist. The patient arrived at a local hospital 3 h after the bite. Upon arrival, the patient was conscious, oriented, and haemodynamically stable with adequate saturation in room air. Systemic examination was unremarkable, and no signs of neurotoxicity were present. The patient displayed bleeding in the gums, localised swelling, right axillary lymphadenopathy, and a prolonged 20 min whole blood clotting time (20 WBCT), which is a classical sign of envenomation. Therefore, he was administered 50 ml (5 vials) of polyvalent antivenom (Bharat Serums and Vaccines Limited, Mumbai, India) raised against the Indian 'Big Four' snakes (Russell's viper, cobra, krait, and saw-scaled viper). Two hours later (i.e., 5 hours



**Fig. 1.** Haemorrhagic manifestations in the adrenal and pituitary glands caused by Russell's viper envenomation in a 42-year-old victim. (A) The offending snake was identified as Russell's viper by a herpetologist. (B) Axial non-contrast CT scan of the brain corroborating acute haemorrhage of the pituitary gland (indicated with an arrow). (C) Coronal view of abdominal CT demonstrating haemorrhagic and enlarged adrenal glands (indicated with arrows). (D, E) Axial views of abdominal CT confirming haemorrhagic adrenal glands (indicated with arrows).

after the bite), he complained of further complications such as palpitations, nausea, and abdominal pain. He became restless and irritable, and his blood pressure dropped down to 70/50 mmHg with a pulse rate of 132 beats per min. He received two doses of intramuscular epinephrine and dexamethasone in suspicion of an early anaphylactic reaction to the antivenom. Following no signs of improvement, he was transferred to the emergency department of our hospital.

Upon arrival, he was unconscious, responding to only deep painful stimuli with a heart rate of 160 bpm and systolic blood pressure of 70 mmHg. Due to a poor response to stimuli in line with a low score on the Glasgow Coma Scale (GCS, which assesses the level of consciousness), and a high risk of impending respiratory arrest and shock, he was intubated and connected to a mechanical ventilator. Fang marks were visible on the right index finger, but no active bleeding was observed. His 20 WBCT and prothrombin times were prolonged. Therefore, he was given 10 vials (in 250 ml of saline) of polyvalent antivenom (Bharat Serums and Vaccines Limited, Mumbai, India) intravenously over 1 hour. An echocardiogram revealed normal left ventricular function and no evidence of pericardial effusion. The chest radiograph was normal. Despite adequate intravenous fluid replacement, he still displayed persistent hypotension, so, intravenous noradrenaline (0.01 µg/kg of body weight until blood pressure improved) infusion was started. He also displayed recurrent episodes of hypoglycaemia despite intravenous dextrose supplementation, with blood sugar levels fluctuating between 45 and 60 mg/dL.

Blood parameters showed sodium level of 135 mEq/L, potassium of 6.9 mEq/L, chloride of 102 mEq/L, bicarbonate of 16 mEq/L, aspartate aminotransferase (AST) 253 IU/L, alanine aminotransferase (ALT) 699 IU/L, the glucose of 52 mg/dL, and creatinine 2.9 mg/dL. His urea, uric acid, and creatinine as well as serum glutamic-oxaloacetic transaminase (SGOT) and serum glutamate pyruvate transaminase (SGPT) levels were increased. Based on catecholamine-resistant hypotension, hypoglycaemia and hyperkalaemia, an adrenal crisis was suspected. His random cortisol level was largely reduced to 1.12 µg/dL (normal levels: 6.2–19.4 µg/dL). Similarly, his thyroid hormone levels were reduced; thyroid stimulating hormone (TSH) - 0.03 µIU/mL (normal levels: 0.30–5.5 µIU/mL), free thyroxine (T4) - 0.41 ng/dL (normal levels: 0.70–1.80 ng/dL) and free triiodothyronine (T3) - 0.6 pg/mL (normal levels: 1.7–4.2 pg/mL). Moreover, growth hormone (0.12 ng/mL), prolactin (1.7 ng/mL), adrenocorticotrophic hormone (ACTH) (5.90 pg/mL), LH (0.11 mIU/mL), follicle-stimulating hormone (FSH) (0.14 mIU/mL), Insulin-like growth factor 1 (IGF1) (25 ng/mL), insulin-like growth factor binding protein 3 (IGFBP3) (1.04 µg/mL), and testosterone (0.20 ng/mL) levels were all reduced. Hence, an emergency computerised tomography (CT) brain scan without contrast was performed, and it revealed an acute haemorrhage in the pituitary gland (Fig. 1B). Similarly, a CT scan of the abdomen showed bilateral homogeneous, smooth adrenal enlargement with high attenuation, suggestive of bilateral adrenal haemorrhage (Fig. 1C, D and E). The replacement of cortisol and thyroxine was performed according to the standard protocol; by giving the patient hydrocortisone 50 mg intravenously twice daily for five days and thyroxine 150 µg (orally as tablets once daily until the euthyroid state was attained). Vasopressors were tapered gradually, and the patient was weaned off the ventilator and extubated on the 9<sup>th</sup> day from admission. His condition improved and he was discharged on day 15 (from admission at our hospital). He was stable during the weekly follow-up monitoring for three months, and once a fortnight for another three months.

### 3. Discussion

The majority of the clinical manifestations of Russell's viper envenomations on biological systems and their implications for effective antivenom therapy have been extensively documented in the literature (Suraweera et al., 2020; Senthilkumaran et al., 2022a). However, recent clinical studies have emphasised that we have a limited understanding

of the full range of possible complications that Russell's viper envenomations can cause including numerous rare manifestations (Pothukuchi et al., 2018; Sasidaran et al., 2018; Ganguly et al., 2022). Several examples of such unusual consequences have been published in recent years (Senthilkumaran et al., 2021b, 2022b; Arathisenthil et al., 2022), warning that healthcare professionals must remain vigilant and observant of unexpected manifestations in SBE victims. New reports of uncommon manifestations are crucial for building awareness and ensuring the effective resolution of symptoms based on previous experiences. This article is an example of a patient with both bilateral adrenal and pituitary haemorrhages caused by Russell's viper bite.

Adrenal glands are important sites for the production and secretion of several hormones, which are intrinsically regulated by signals from the pituitary gland in the brain (Goyal et al., 2018). These glands are richly covered with blood vessels and therefore, they are highly susceptible to bleeding (Bhattacharya et al., 2020). Many different causative factors such as acute stress, anticoagulant use, burns, COVID-19, infections, idiopathies, liver transplantation, major surgery, severe sepsis, and tumours may induce adrenal haemorrhages (Wong et al., 2016). Bleeding into the pituitary gland induced by diverse factors also has numerous causalities (Uihlein et al., 1957). The data presented here, including symptoms, laboratory results and imaging modality indicates Russell's viper envenomation as a possible cause of haemorrhage of the pituitary and adrenal glands. A considerable percentage (51%) of such bleeding events have been identified in autopsies involving the adrenal and pituitary glands of victims in India following Russell's viper envenomation (Gopalakrishnan et al., 2018).

An investigation of SBE cases in Myanmar revealed that around 90% of the patients' autopsies within a 5-year period were victims of Russell's viper envenomations. This study revealed a similar prevalence of pituitary (43%) and adrenal (36%) haemorrhages among other SBE patients (Thein and Byard, 2019). Other studies have discussed patient fatalities resulting from haemorrhages of the adrenal or pituitary glands induced by Russell's viper (Tun et al., 1987; Than et al., 1989). These insights suggest that such complications may be more frequent than previously realised. Thus, more statistical analysis of observational data is needed to confirm if they are uncommon or rather underreported manifestations.

To date, the relationship between SBE and haemorrhagic necrosis of pituitary or adrenal glands has not been completely understood (Bhattacharya et al., 2020). The high blood supply requirements of these glands make them a likely site of blood extravasation induced by venom toxins (Jordan et al., 2012). Functional studies have unveiled that biologically active toxic proteins within Russell's viper venom present vasculotoxic, haemorrhagic and proteolytic properties which may lead to venom-induced thrombocytopenia, activation of clotting factors and fibrinolysis. Activation of clotting factors paired with excessive fibrinolysis results in the exhaustion of clotting factors and is known as consumption coagulopathy. The venom-induced consumption coagulopathy can result in localised blood clotting with systemic bleeding a condition known as disseminated intravascular coagulation. This coincides with the prolonged 20 WBCT and prothrombin time observed in this SBE patient. The consumption of coagulation factors and/or direct action of snake venom metalloproteases on blood cell wall integrity is a possible pathogenic mechanism implicated in the reported disturbance of the functional vascular network. Other similar reports previously support the same mechanistic details as discussed here (Lakhotia et al., 2014; Kar et al., 2021).

The non-specific presentation and diagnostically challenging nature of haemorrhages in endocrine glands were illustrated in this case report. Initially, adrenaline and glucocorticoid (dexamethasone) were given to prevent/revert potentially serious hypersensitivity effects characteristic of an anaphylactic reaction. These strategies are widely used to avoid adverse events derived from the antivenom (Nuchpraryoon and Garner., 2000). However, in the present case, this intervention did not eliminate the symptoms, suggesting a misdiagnosis. The patient required



transferring to another specialist hospital for better management, emphasising the need for more well-trained clinicians to handle SBE victims and this is the same in many developing countries (Vaiyapuri et al., 2013). Strengthening health centres and training medical personnel for accurate and time-limited diagnosis are key points to achieve the objectives of mitigating the impact of SBE in line with the strategies established by the World Health Organisation (Minghui et al., 2019). The victim in this study experienced acute abdominal pain, hypotension that did not respond to inotropes, hypoglycaemia, and hyperkalaemia. Additionally, of clinical significance, laboratory test results confirmed decreased cortisol, thyroid stimulating hormone, prolactin, free triiodothyronine (T3), free thyroxine (T4), testosterone and ACTH levels. Collectively, these biomarkers are correlated with adrenal insufficiency, as suggested by previous studies (Senthilkumaran et al., 2018; Bhattacharya et al., 2020). In line with this suspicion of endocrine dysfunction, a CT scan was performed. CT examinations of the brain and abdomen are key imaging modalities used for diagnosing haemorrhage in endocrine glands (Sayit et al., 2017; Goyal et al., 2018). According to our image analysis, the SBE victim presented simultaneous bilateral adrenal and pituitary haemorrhages. Thus, this case consists of primary and secondary adrenal insufficiency characterised by damage to the adrenal and pituitary glands, respectively. Most previously reported cases of patients bitten by snakes with haemorrhage are in one of the glands. In this sense, we encourage prompt diagnosis allowing for the timely provision of life-saving treatments.

In clinical practice, the general management of SBE victims presenting adrenal and/or pituitary haemorrhages is frequently based on hormones, replacing those that are not being produced due to venom-induced effects on the endocrine gland (Fatima et al., 2018). In this study, conservative therapy consisting of a combination of hydrocortisone and thyroxine was successful. Similarly, Russell's viper patients showing bilateral adrenal haemorrhages exhibited considerable improvement in the clinical condition following traditional approaches involving the administration of intravenous hydrocortisone (Senthilkumaran et al., 2018). From a hospital-based supportive care experience, other reviews, case reports and original articles have evidenced the important role of corticosteroid treatment in high-risk patients (Rao et al., 1989; Bhandari et al., 2016; Senthilkumaran et al., 2018; Bashari et al., 2020).

Finally, bilateral adrenal and pituitary complications should be considered during medical supervision of victims bitten by Russell's viper and other snakes, and healthcare professionals must be vigilant in promptly identifying these events. The underlying mechanisms causing these effects have not been fully elucidated. Thus, multidisciplinary research into these consequences, including a detailed epidemiology analysis and molecular research should be initiated for a deeper understanding that could result in beneficial therapeutic developments and drive decision-making that can have a direct impact on the advancement of clinical practice.

#### 4. Conclusions

This case report updates the recognised clinical presentations of Russell's viper envenomations and offers a detailed account of the diagnosis and treatment of simultaneous haemorrhage in adrenal and pituitary glands, which can be utilised as a guide for the successful treatment of future patients displaying similar clinical manifestations and symptomology. In summary, bilateral adrenal and pituitary haemorrhages caused by Russell's viper bites seem to be underreported conditions that require due care and consideration when dealing with patients and assessing their signs and symptoms. Failure or delay in acknowledging these clinical manifestations and administering appropriate treatment can be fatal. The exact pathophysiology of this clinical scenario remains uncertain and deserves further investigation. In terms of successful management, early diagnosis using a CT scan and prompt administration of parenteral hydrocortisone are essential to improve

patient outcomes.

#### Credit author statement

**Subramanian Senthilkumaran:** Conceptualization, Methodology, Validation, Investigation, Resources, Data Curation, Visualization, Supervision. **José R. Almeida:** Writing - Original Draft, Writing - Review & Editing, Visualization. **Jarred Williams:** Writing - Original Draft, Writing - Review & Editing, Visualization. **Harry F. Williams:** Formal analysis, Writing - Review & Editing-. **Ponniiah Thirumalaikolundusubramanian:** Formal analysis, Validation, Investigation, Resources, Data Curation, Writing - Review & Editing, Supervision. **Ketan Patel:** Formal analysis, Resources, Writing - Review & Editing. **Sakthivel Vaiyapuri:** Formal analysis, Validation, Investigation, Resources, Data Curation, Writing - Original Draft, Writing - Review & Editing, Visualization, Supervision.

#### Ethical statement

This study was performed in line with the Declaration of Helsinki, and permitted by the Institutional Ethics Committee of Toxiven Biotech Private Limited (2019-001/002 on the October 11, 2019). Written informed consent was obtained from the patient to collect and publish this data.

#### Declaration of competing interest

The authors declare that they have no known competing financial interests or personal relationships that could have appeared to influence the work reported in this paper.

#### Data availability

All the data are presented in this article.

#### Acknowledgements

The authors would like to thank the Medical Research Council, UK (reference: MR/W019353/1 & Integrative Toxicology Training Partnership – PhD studentship) for their funding support.

#### References

- Adhikari, R.B., et al., 2019. Clinico-epidemiology and management of Russell's viper (*Daboia russelii*) envenoming in dogs in Sri Lanka. *Toxicol Rep* 6, 809–818.
- Arathisenthil, S.V., et al., 2022. Rapid development of a salivary calculus in submandibular gland and its potential causes in a young victim following Russell's viper bite. *Toxicol* 206, 85–89.
- Arnold, C., 2020. Snakebite steals millions of years of quality life in India. *Nature PMID*, 33277637.
- Bashari, W.A., et al., 2020. Adrenal insufficiency secondary to bilateral adrenal hemorrhage: a case report. *Cureus* 12, e8596.
- Bhandari, S., et al., 2016. Bilateral adrenal hemorrhage in polycythemia vera. *J. Community Hosp. Intern. Med. Perspect.* 6, 32416.
- Bhattacharya, S., et al., 2020. Endocrine and metabolic manifestations of snakebite envenoming. *Am. J. Trop. Med. Hyg.* 103, 1388–1396.
- Fatima, Z., et al., 2018. A rare case of bilateral adrenal hemorrhage. *Cureus* 10.
- Ganguly, D., et al., 2022. Bilateral parotid swelling in viper bite: further evidence for a poor prognosis. *BMJ Case Rep.* 15, e252217.
- Gopalakrishnan, M., et al., 2018. Exploring circulatory shock and mortality in viper envenomation: a prospective observational study from India. *QJM* 111, 799–806.
- Goyal, P., et al., 2018. Clinical and imaging features of pituitary apoplexy and role of imaging in differentiation of clinical mimics. *Quant. Imag. Med. Surg.* 8, 219–231.
- Jordan, E., et al., 2012. Imaging of nontraumatic adrenal hemorrhage. *Am. J. Roentgenol.* 199, W91–W98.
- Kar, K., et al., 2021. Endocrine dysfunctions may be sequelae of snake bite. *Asian J. Med. Sci.* 12, 150–155.
- Kim, D.J., et al., 2009. Pituitary hemorrhage : classification and related factors. *J Korean Neurosurg Soc* 46, 23–30.
- Kolinioti, A., et al., 2018. Acute adrenal insufficiency due to adrenal hemorrhage complicating colorectal surgery: report of two cases and correlation with the antiphospholipid antibody syndrome. *International Journal of Surgery Case Reports* 51, 90–94.

- Lakhotia, M., et al., 2014. Adrenal hematoma and right hemothorax after echis carinatus bite: an unusual manifestation. *Toxicol. Int.* 21, 325–327.
- Larréché, S., et al., 2021. Bleeding and thrombosis: insights into pathophysiology of Bothrops venom-related hemostasis disorders. *Int. J. Mol. Sci.* 22.
- Longbottom, J., et al., 2018. Vulnerability to snakebite envenoming: a global mapping of hotspots. *Lancet* 392, 673–684.
- Minghui, R., et al., 2019. WHO's Snakebite envenoming strategy for prevention and control. *Lancet Global Health* 7, e837–e838.
- Nuchpraryoon, I., Garner, P., 2000. Interventions for Preventing Reactions to Snake Antivenom. *Cochrane Database Syst Rev*, p. Cd002153, 1999.
- Pothukuchi, V., et al., 2018. A rare case report of Russell's viper snakebite with ischemic stroke. *Hong Kong J. Emerg. Med.* 25, 95–97.
- Rao, R.H., Vagnucci, A.H., Amico, J.A., 1989. Bilateral massive adrenal hemorrhage: early recognition and treatment. *Ann. Intern. Med.* 110, 227–235.
- Samuel, S.P., et al., 2020. Venomous snakebites: rapid action saves lives-A multifaceted community education programme increases awareness about snakes and snakebites among the rural population of Tamil Nadu, India. *PLoS Neglected Trop. Dis.* 14, e0008911.
- Sasidaran, M.N., et al., 2018. Parotid swelling after Russell's viper envenomation: an unusual and poor prognostic sign. *Clinical Case Reports* 6, 262–266.
- Sayit, A.T., et al., 2017. Imaging of unilateral adrenal hemorrhages in patients after blunt abdominal trauma: report of two cases. *Chin. J. Traumatol.* 20, 52–55.
- Senthilkumaran, S., et al., 2018. Russell's viper envenomation-associated Addisonian crisis. *Wilderness Environ. Med.* 29, 504–507.
- Senthilkumaran, S., et al., 2021a. Splenic rupture and subsequent splenectomy in a young healthy victim following Russell's viper bite. *Toxicon* 204, 9–13.
- Senthilkumaran, et al., 2021b. Priapism following a juvenile Russell's viper bite: an unusual case report. *PLoS Neglected Trop. Dis.* 15, e0009242.
- Senthilkumaran, S., et al., 2022a. Development of Wunderlich syndrome following a Russell's viper bite. *Toxicon* 215, 11–16.
- Senthilkumaran, S., et al., 2022b. Ultrasound-guided compression method effectively counteracts Russell's viper bite-induced pseudoaneurysm. *Toxins* 14.
- Sharrack, N., et al., 2020. Adrenal haemorrhage as a complication of COVID-19 infection. *BMJ Case Rep.* 13, e239643.
- Simon, D.R., Palese, M.A., 2009. Clinical update on the management of adrenal hemorrhage. *Curr. Urol. Rep.* 10, 78–83.
- Suraweera, W., et al., 2020. Trends in snakebite deaths in India from 2000 to 2019 in a nationally representative mortality study. *Elife* 9.
- Than, T., et al., 1989. Contribution of focal haemorrhage and microvascular fibrin deposition to fatal envenoming by Russell's viper (*Vipera russelli siamensis*) in Burma. *Acta Trop.* 46, 23–38.
- Thein, C.M., Byard, R.W., 2019. Characteristics and relative numbers of lethal snake bite cases in medicolegal practice in central Myanmar – a five year study. *Journal of Forensic and Legal Medicine* 63, 52–55.
- Thorpe, R.S., Pook, C.E., Malhotra, A., 2007. Phylogeography of the Russell's viper (*Daboia russelii*) complex in relation to variation in the colour pattern and symptoms of envenoming. *Herpetol. J.* 17, 209–218.
- Tun, P., et al., 1987. Acute and chronic pituitary failure resembling Sheehan's syndrome following bites by Russell's viper in Burma. *Lancet* 2, 763–767.
- Uihlein, A., Balfour, W.M., Donovan, P.F., 1957. Acute hemorrhage into pituitary adenomas. *J. Neurosurg.* 14, 140–151.
- Vaiyapuri, S., et al., 2023. Multifaceted community health education programs as powerful tools to mitigate snakebite-induced deaths, disabilities, and socioeconomic burden. *Toxicon X* 17, 100147.
- Vaiyapuri, S., et al., 2013. Snakebite and its socio-economic impact on the rural population of Tamil Nadu, India. *PLoS One* 8, e80090.
- Williams, H.F., et al., 2017. Challenges in diagnosing and treating snakebites in a rural population of Tamil Nadu, India: the views of clinicians. *Toxicon* 130, 44–46.
- Wong, K.K., et al., 2016. Chapter 106 - adrenal gland imaging. In: Jameson, J.L., De Groot, L.J., de Kretser, D.M., Giudice, L.C., Grossman, A.B., Melmed, S., Potts, J.T., Weir, G.C. (Eds.), *Endocrinology: Adult and Pediatric*, seventh ed. W.B. Saunders, Philadelphia, pp. 1841–1861. e1844.