

*Third fragment femoral shaft fracture: a retrospective analysis of complications and predictive factors for non-union and delayed union*

Article

Published Version

Creative Commons: Attribution 4.0 (CC-BY)

Open Access

Gambutì, E., Caldaria, A., Spadoni, E., Biagi, N. ORCID: <https://orcid.org/0000-0002-7119-0767>, Azzolina, D., Saracco, A., Guerzoni, M. V., Massari, L. and Caruso, G. (2025) Third fragment femoral shaft fracture: a retrospective analysis of complications and predictive factors for non-union and delayed union. *Orthopaedics & Traumatology: Surgery & Research*, 111 (7). 104295. ISSN 1877-0568 doi: 10.1016/j.otsr.2025.104295 Available at <https://centaur.reading.ac.uk/129726/>

It is advisable to refer to the publisher's version if you intend to cite from the work. See [Guidance on citing](#).

To link to this article DOI: <http://dx.doi.org/10.1016/j.otsr.2025.104295>

Publisher: Elsevier

All outputs in CentAUR are protected by Intellectual Property Rights law, including copyright law. Copyright and IPR is retained by the creators or other

copyright holders. Terms and conditions for use of this material are defined in the [End User Agreement](#).

[www.reading.ac.uk/centaur](http://www.reading.ac.uk/centaur)

## **CentAUR**

Central Archive at the University of Reading

Reading's research outputs online



Contents lists available at ScienceDirect

# Orthopaedics & Traumatology: Surgery & Research

journal homepage: [www.sciencedirect.com/journal/orthopaedics-and-traumatology-surgery-and-research](http://www.sciencedirect.com/journal/orthopaedics-and-traumatology-surgery-and-research)



Original article

## Third fragment femoral shaft fracture: A retrospective analysis of complications and predictive factors for non-union and delayed union

Edoardo Gambuti<sup>a</sup>, Antonio Caldaria<sup>a</sup>, Elisa Spadoni<sup>a</sup>, Nicolò Biagi<sup>b</sup>, Danila Azzolina<sup>c</sup>,  
Achille Saracco<sup>a</sup>, Maria Vittoria Guerzoni<sup>a</sup>, Leo Massari<sup>d</sup>, Gaetano Caruso<sup>a,\*</sup>

<sup>a</sup> Department of Neurosciences and Rehabilitation, University of Ferrara, Via Aldo Moro 8, 44124 Ferrara, Italy

<sup>b</sup> Henley Business School, Business Informatics Systems and Accounting, Informatics Research Centre, University of Reading, United Kingdom

<sup>c</sup> Department of Environmental and Preventative Sciences, University of Ferrara, Via Luigi Borsari 46, 44121 Ferrara, Italy

<sup>d</sup> Department of Translational Medicine and for Romagna, University of Ferrara, Via Moro 8, 44124 Ferrara, Italy



### ARTICLE INFO

#### Keywords:

Third fragment  
Femoral fracture  
Delayed union  
Risk factors  
Non-union

### ABSTRACT

**Introduction:** Diaphyseal femur fractures are relatively common, and up to 39% of these cases involve a third fragment. These types of fractures present a unique challenge due to their high risk of non-union, reported in up to 14% of cases. Despite their frequency, there is still no consensus on the optimal management of the third fragment in these fractures.

The purpose of this retrospective study was to compare the clinical and radiological outcomes of patients who underwent reduction of the third fragment with those who did not, to determine the characteristics of the third fragment that warrant reduction, and to suggest the best approach.

The hypothesis is that an open reduction of the third fragment is to be avoided as it increases the risk of non-union.

**Material and methods:** This retrospective monocentric study analysed clinical data from patients diagnosed with diaphyseal femur fractures at our Unit between 2010 and 2022. Radiological data encompassed the length and width of the third fragment, the fracture gap, its proximity to the proximal and distal cortex, the greatest cortex-to-cortex distance, and the orientation of the third fragment. Other factors considered included patient age, BMI, sex, type of surgery performed, fracture fixation method, occurrence of complications, specific complication types, incidence of mortality, and duration of follow-up.

**Results:** Seventy patients were included in the study; 24 patients underwent osteosynthesis with plates and screws, while 46 patients were treated with intramedullary nailing. Descriptive analysis revealed no statistically significant difference in the characteristics of the third fragment between patients who experienced complications and those who did not.

Surgical technique for osteosynthesis (plates and screws Vs intramedullary nailing) also showed no statistically significant differences, conversely the open reduction and synthesis of the third fragment is a statistically significant complication predictor.

**Conclusion:** The management of the third fragment remains a challenge. In our series of patients third fragment characteristics and type of osteosynthesis did not influence the risk of complications. However, the determining factor was found to be the open reduction of the third fragment.

**Level of evidence:** IV

### 1. Introduction

Diaphyseal femur fractures are relatively common. Erivan et al. report an average of 10,617 femoral diaphysis fractures per year in France between 2013 and 2021 [1]. Intramedullary nailing has long

been considered the preferred treatment for these fractures due to its favourable outcomes [2,3]. However, approximately 10–34% of femoral fractures present a three-fragment configuration with a sizable butterfly fragment, classified as type 32B according to the AO/OTA classification system. These types of fractures, characterized by the presence of a third

\* Corresponding author.

E-mail address: [crsgtn@unife.it](mailto:crsgtn@unife.it) (G. Caruso).

<https://doi.org/10.1016/j.otsr.2025.104295>

Received 24 September 2024; Accepted 19 May 2025

Available online 20 May 2025

1877-0568/© 2025 The Author(s). Published by Elsevier Masson SAS. This is an open access article under the CC BY license (<http://creativecommons.org/licenses/by/4.0/>).

fragment, pose a unique challenge for orthopaedic surgeons. These fractures have a high risk of non-union, occurring in up to 14% of cases [4], and there is currently no consensus on the optimal management of the third fragment. Understanding the risks associated with non-union and delayed union is critical to preventing potential complications of such fractures.

In 2022, Yang S. et al. reported a low union rate in fractures with a significantly displaced or reversed third fragment, indicating that the anatomical reduction should aim to bring the fragment as close as possible to its original position [5]. Conversely, Laydown et al. reported a union rate of 92% for flipped intercalary fragments with t closed reduction and intramedullary nailing [6].

Hamahashi et al. suggested that the degree of comminution of the third fragment is a key factor contributing to delayed union [7]. However, the healing time may be affected by the blood supply disruption, which can occur as a result of open reduction and internal fixation. This highlights the ongoing debate regarding the indications for open reduction of free fracture fragments following intramedullary nailing, as well as the optimal method of fixation after reduction [8].

The purpose of this retrospective study was to compare the clinical and radiological outcomes of patients who underwent anatomical reduction of the third fragment with those who did not, to determine the characteristics of the third fragment that warrant reduction, and to suggest the best approach.

The hypothesis is that an open reduction of the third fragment is to be avoided as it increases the risk of non-union.

## 2. Patients, methods and procedure

### 2.1. Patients

A retrospective analysis was conducted on a consecutive series of diaphyseal femur fractures, treated with osteosynthesis, performed from April 2010 until March 2022 at our Unit.

Inclusion criteria for the study were diaphyseal femur fracture with a

third fragment (types 32B2 and 32B3 according to the AO-OTA classification), a minimum follow-up period of twelve months, and patients who were of legal adult age. Exclusion criteria included fractures classified as AO-OTA 32A and 32C, periprosthetic fracture, and cases without sufficient radiological or clinical data.

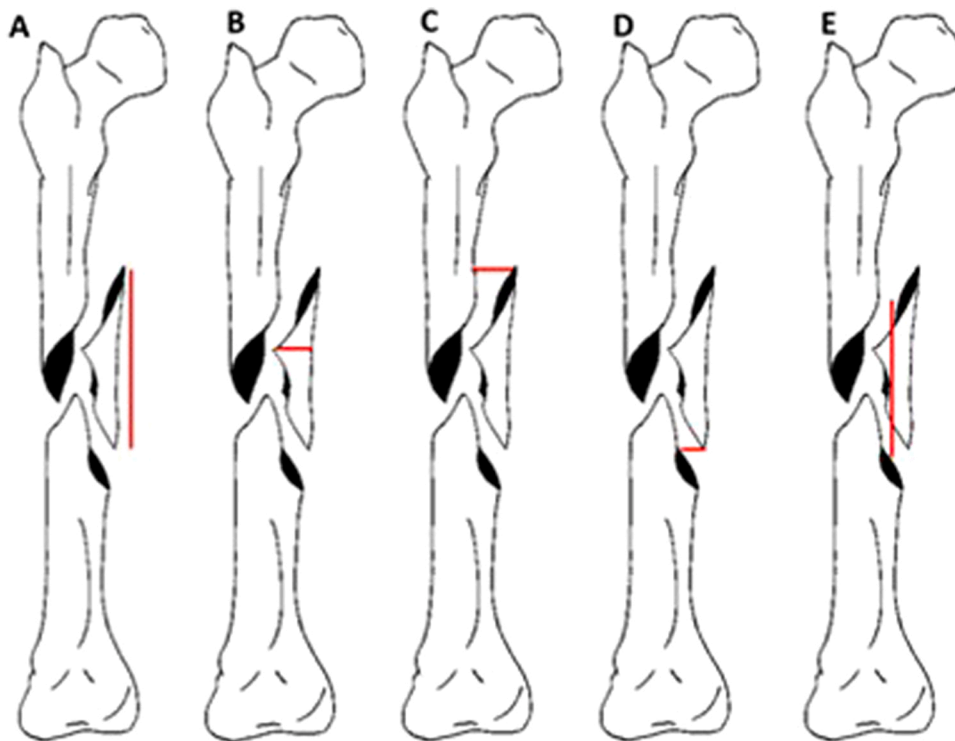
### 2.2. Methods of assessment

Data were extracted from our hospital's electronic clinical records database, including general patient information, medical history, clinical and radiological findings, surgical procedures, and follow-up data. The fractures were classified by the senior author (L.M.) using the AO classification and The Orthopaedic Trauma Association Classification of Fractures.

True anteroposterior and lateral view radiographs were performed and examined by one independent fellowship-trained examiner (E.G.) using picture-archiving communication system (PACS) software. Bone union fractures were defined as the presence of bony continuity in at least three cortices on both anteroposterior and lateral femoral radiographic views. Non-union fractures, on the other hand, were characterized according to FDA guidelines [8], as a fracture that persists without evidence of healing for a minimum of 9 months, without signs of healing for three consecutive months. Additionally, we classified a failed osteosynthesis as a form of non-union. Delayed fracture union was defined as a healing duration of 4–6 months [9].

The factors analysed in this study included: the length and width of the third fragment, the size of the fracture gap and the proximity of the fragment to the proximal and distal cortex (Fig. 1). The greatest cortex-to-cortex distance was obtained by considering the highest value between the proximal cortex-to-cortex distance and the distal cortex-to-cortex distance.

Additional factors include: the type of surgery performed, fracture fixation method (intramedullary nail or plate and screws), presence and type of complications, incidence of mortality, duration of follow-up in months, patient age, BMI, and sex. Only local complications were



**Fig. 1.** Measurement of the third fragment: (A) length; (B) width; (C) proximal cortex-to-cortex distance; (D) distal cortex-to-cortex distance; (E) fracture gap: measurement obtained from the most proximal point to the most distal point of the fracture; Original drawing from one of the authors of the article (E.S.).

considered for this analysis.

2.3. Procedure

Two different surgical approaches were chosen to treat third fragment fractures; intramedullary nailing or plate and screws. The plate and screw fixation was performed in according to the main AO/OTA recommendations. The two main fragments, proximal and distal, were stabilized with at least 3-4 screws in each major fragment, primarily with the use of locking screws. The third fragment synthesis was performed with interfragmentary screws. The length of the plate was 3 times the length of the fracture. Where as for a non synthesised third fragment, bridge plating was used as the preferred technique.

Furthermore, in patients treated with intramedullary nail, we performed open reduction with cerclage wire fixation.

The study was approved by the local University-Hospital Human Subject Research Ethics Committee (Comitato Etico Indipendente di Area Vasta Emilia Centro—CE-AVEC 543/2022/Oss/AOUFe 14/09/2022).

All data collection and analysis were conducted in accordance with the principles outlined in the Declaration of Helsinki.

2.4. Statistical analysis

A comprehensive analysis was conducted to determine the impact of covariates on the presence of complications, such as non-union and delayed healing. The initial phase of the analysis involved comparing groups based on the presence or absence of complications and comparing different types of complications (no complications, non-union, and delayed healing).

Continuous data are reported as mean, while categorical data are presented as percentages and absolute frequencies. Independent t-tests were used for normally distributed numerical variables, while Wilcoxon rank sum tests were used for non-normally distributed data. One-way ANOVA was applied to compare three complication groups when assumptions were met, while Kruskal-Wallis tests were used for non-normally distributed data. Chi-square tests or Fisher's exact tests were performed to compare categorical variables as appropriate.

To investigate whether specific third fragment characteristics were associated with complications, Wilcoxon rank sum tests (for non-normal distributions) and t-tests (for normally distributed variables) was used.

A Chi-square independence test was conducted to evaluate the association between Complications and Osteosynthesis.

To further examine whether third fragment characteristics varied by complication type, we conducted one-way ANOVA (when assumptions were met) and Kruskal-Wallis tests (for non-normal distributions).

Additionally, a multinomial logistic regression was conducted to assess the predictors of specific types of complications.

Statistical analyses were performed using R software (R Core Team, 2024, Vienna, Austria) and RStudio (RStudio Team, 2020, Boston, MA, USA). The following R packages were utilized: rstatix (Kassambara, 2023), nnet & MASS (Venables & Ripley, 2002), and car (Weisberg, 2019).

3. Results

Out of the initial 370 patients evaluated, only 70 met the pre-defined selection criteria (Fig. 2). The characteristics of these patients are summarized in Table 1.

In accordance with the objective of the study, the characteristics of the third fragment were analyzed first.

The characteristics of the third fragment are detailed in Table 2. No

Table 1

Summary of characteristics of patients included in the study.

Patients' characteristics	
Age	46.8 ± 6.1
Sex	50 M (71.4%); 20 F (28.6%)
BMI	26.6 ± 6.1
Follow-up	10.48 ± 7.48 months
Fracture Classification	36 32B-2 (51.4%); 34 32B-3 (48.6%)
Surgical procedure	24 (34.3%) plate and screw; 46 (65.7%) intramedullary nailing
Third Fragment Synthesis	24 Synthesis (34.3%); 46 non Synthesis (65.7%)
Complications	22 (31.4%) (11 non-unions; 11 delayed unions)
Deaths	8 (11.4%)

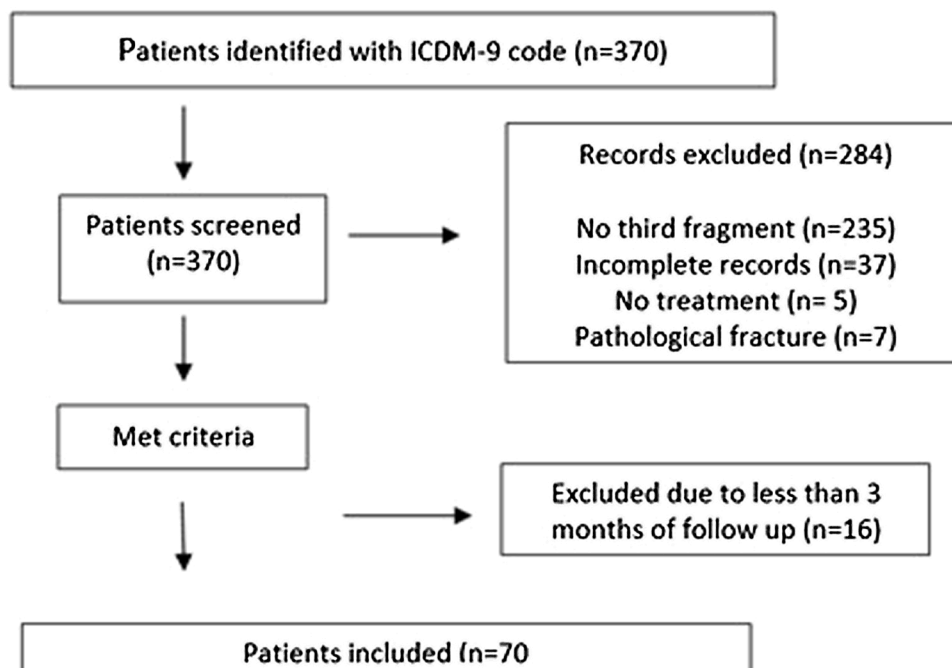


Fig. 2. Study flowchart.

**Table 2**  
Summary of fragment characteristics.

Fragment characteristics	
Fragment Length (mm)	112.65 mm ± 103.32 mm
Fragment Width (mm)	21.42 mm ± 7.60 mm
Proximal cortex-to-cortex distance (mm)	5.38 mm ± 11.38 mm
Distal cortex-to-cortex distance (mm)	12.74 mm ± 9.22 mm
Greatest cortex-to-cortex distance (mm)	19.9 mm ± 10.78 mm
Fracture Gap (mm)	67.05 mm ± 36.68 mm

statistically significant difference was found in the third fragment characteristics between patients who developed complications and those who did not (Fig. 3).

Furthermore, no significant differences were found in the size of the third fragment between patients who developed non-union, delayed union and those who did not (Fig. 4).

Next, we aimed to investigate whether there are statistically significant differences in complications between the two types of procedures.

24 patients (34.3%) underwent surgical osteosyntheses of the fracture using plates and screws, while 46 patients (65.7%) were treated with intramedullary nailing. Among the patients who underwent surgical osteosynthesis using plates and screws, 7 patients developed non-union of the fracture (29.1%).

In the group treated with intramedullary nails, 15 complications (32.6%) were observed, including 11 cases of delayed union and 4 cases of non-union. Of course, all patients who developed a non-union developed a delayed union first. However, in the first group of patients (plate and screws group) the delayed union was followed by a non-union. In patients treated with intramedullary nail only 26.7% developed a non-union after a delayed union. A Chi square test was used to assess the association between the type of synthesis (intramedullary nailing or plates and screw) and the presence or absence of complications. The result was not statistically significant ( $\chi^2 (1, n = 70) = 0.84, p = 0.302$ ) (Fig. 5).

Finally, we evaluated the association between the synthesis and non-synthesis of the third fragment and the complications implied. (Fig. 6).

Of the 70 patients included in the study, 24 underwent osteosynthesis of the third fragment; 8 of these were treated via intramedullary nail with open reduction and cerclage, in which 3 developed a non-union, whereas 16 were treated with plates and screws, of whom only 4 developed a non-union. Resulting in a total of 7 non-unions out of the 24 patients included in the group (29.1%).

Within the remaining 46 patients, who did not undergo osteosynthesis of the third fragment, 8 of these patients were treated using plate and screws, whereas 36 were treated using only intramedullary nailing. The former developed 1 non-union (12.5%) and the latter developed 11 delayed union and 3 non-union (37.5%).

Therefore, among the 46 patients who did not undergo osteosynthesis of the third fragment, 15 (19.5%) experienced complications; 11 patients developed delayed union (which ultimately resulted in healing of the fracture) and 4 non-union.

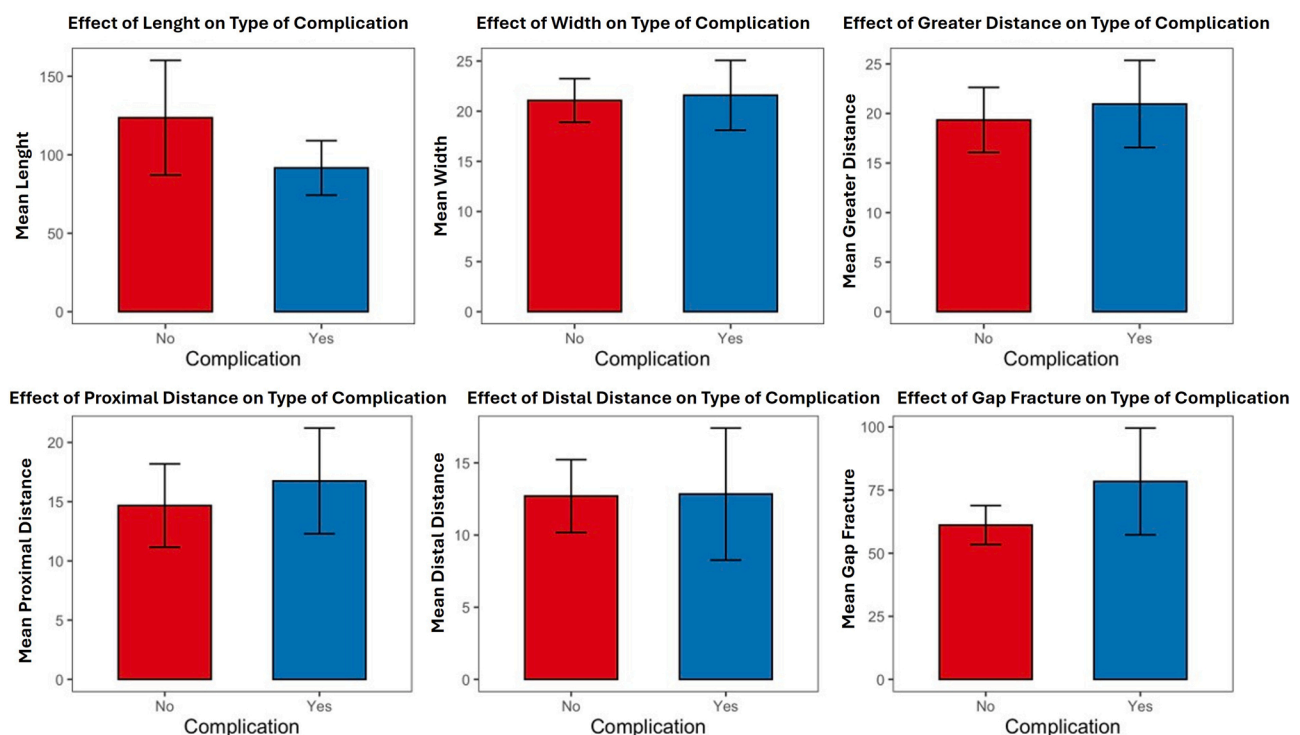
After these results a multinomial logistic regression was performed considering "Type of Complication" as the dependent variable. The result obtained indicates that synthesis of the third fragment is a complication predictor. In particular, the synthesis of the third fragment lead to an increased risk of non-union ( $\chi^2 (2) = 6.43, p = 0.040$ ). While no significant statistical differences were encountered in the methods used for osteosynthesis of the third fragment ( $\chi^2 (2) = 4.88, p = 0.087$ ).

#### 4. Discussion

This study provides valuable insights into the clinical and radiographic outcomes of managing diaphyseal femur fracture with a third fragment using two prevalent surgical techniques: intramedullary nailing and plating with screws.

Diaphyseal femoral fracture characterized by the presence of a third fragment, presents unique challenges for orthopaedic surgeons. These fractures carry a high risk of non-union, which can occur in up to 14% of cases [4]. However, the optimal treatment for these fractures remains a "dilemma".

Based on our results, diaphyseal fractures with a third fragment are complex fractures to treat with a high complication rate. However,



**Fig. 3.** Effect of fragment characteristics on complications.

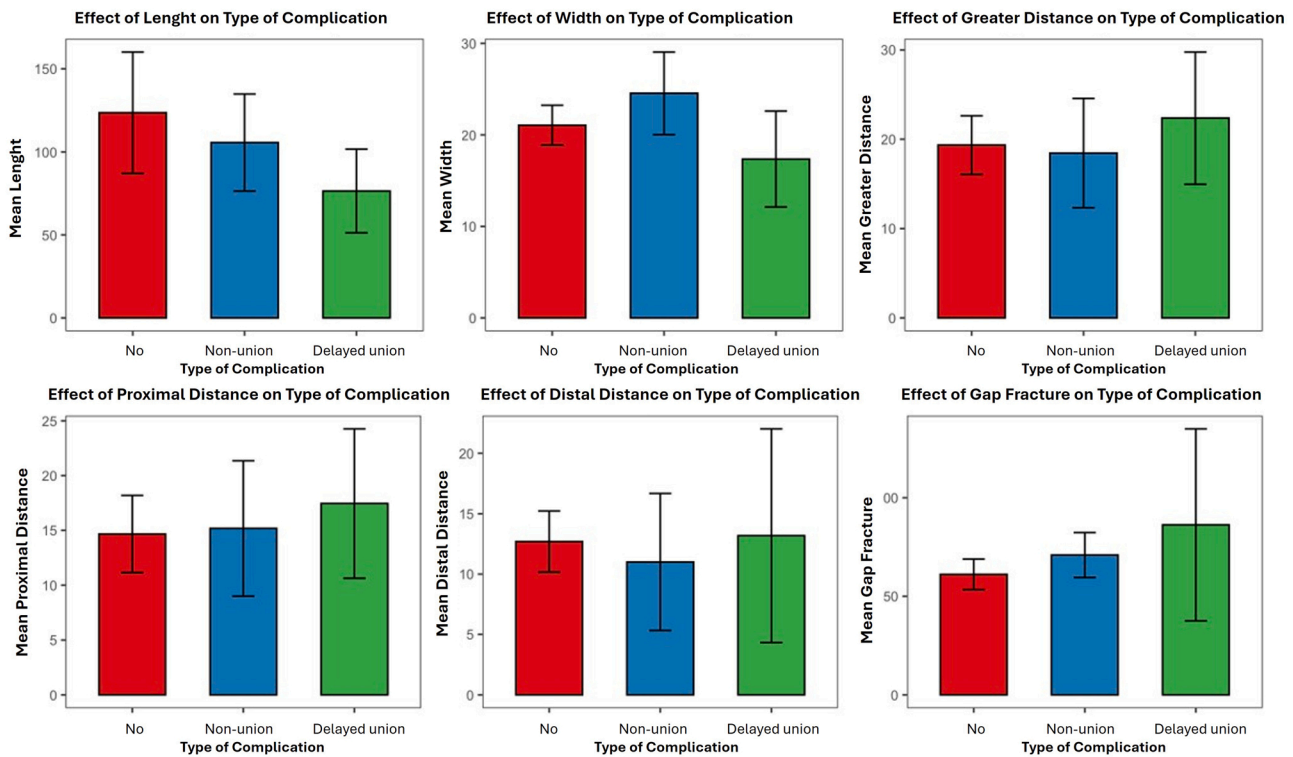


Fig. 4. Effect of fragment characteristics on non-union and delayed union.

## Complication vs Osteosynthesis

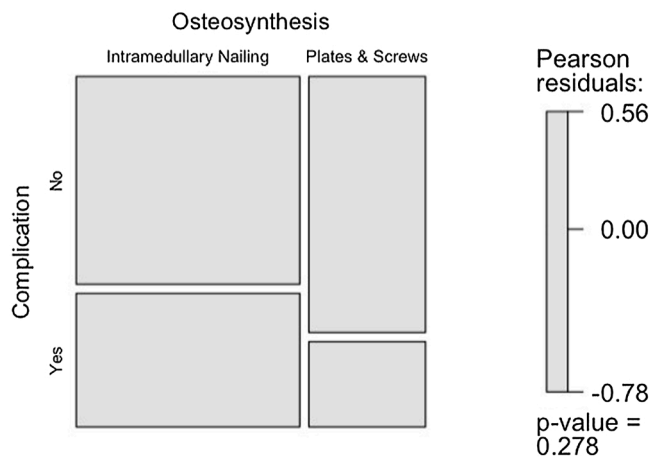


Fig. 5. Relationship between complication and type of surgery.

based on our study, the morphometric features of the third fragment do not influence the likelihood of developing complications. This is in contrast with the findings of other authors. In fact, Vincenti et al. [9] identified that a third fragment with a size greater than 40 mm and displacement exceeding 12 mm were the critical parameters affecting fracture healing. Similarly, Lee et al. reported a higher incidence of non-union with displacements greater than 20 mm [10]. Similar findings were reported by Yang S et al. [5], highlighting the correlation between increasing fragment distance and prolonged union time.

Louka JG et al. analysed 93 patients treated for femoral shaft fractures type 32 B. In this series a displacement greater than 14 mm lead to an increased risk of non-union or delayed healing. The authors

concluded that a fragment displacement of 14 mm or greater leads to 15 times higher risk of non-union or delayed union [11].

Hamahashi K et al. analysed 51 patients treated with intramedullary nailing for third fragment femoral fracture. Multiple logistic regression identified the displacement of the third fragment as the most important risk factor for delayed union [12].

However, in our study the results were different. In fact, the size of the third fragment did not influence the risk of complications.

What differentiates our study are how different surgical techniques were compared (intramedullary nail and plates and screw) with or without third fragment reduction. On the contrary, the cases analysed in the above mentioned studies, only considered one type of intervention without a third fragment reduction.

Performing an open reduction of the third fragment may have influenced the results of our series.

Based on the results of our study the most important finding is that the synthesis of the third fragment is a complication predictor regardless of the fixation method used. Yin Z. et al. [13] analysed 142 patients with third fragment femoral fracture. The overall healing rate was 73.4%. Logistic regression analysis revealed that increased displacement of the third fracture fragments was associated with reduced fracture healing rates. If reduction of the third fragment is required, the authors recommend using indirect reduction methods [13].

Similar findings were reported by Tsai YH et al. [14]. In this study, 80 patients were analyzed. 20 patients were managed with intramedullary nailing and open reduction with fixation of the third fragment. 60 patients were treated with intramedullary nailing without third fragment synthesis. After the statistical analysis authors noted that fixation of the third fragment lead to a longer union time and increased the risk of non-union [14].

In our series, both screw fixation and open reduction with cerclage led to an increased risk of non-union. Cerclage wires presented the risk of vascular strangulation, potentially compromising fracture healing [15]. In both cases, open reduction hinders the hematoma healing process. Preserving the fracture hematoma helps create an osteo-inductive environment that enhances the healing process of the

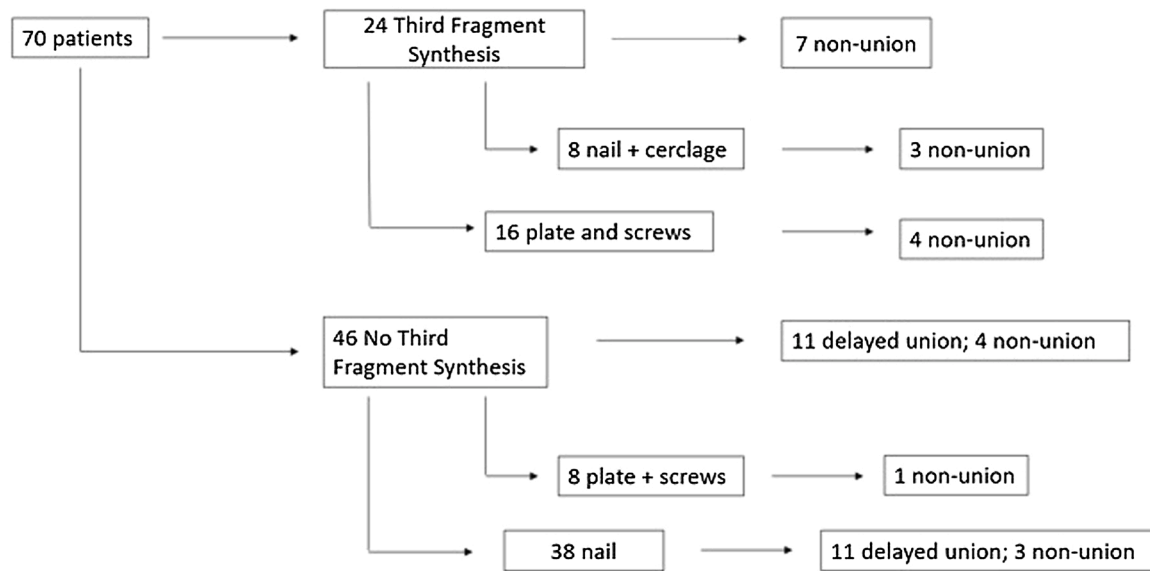


Fig. 6. Division of patients by type of surgery and summary of complications encountered.

fracture [16]. Furthermore, the fracture hematoma also stimulates neo-angiogenesis [17].

The four fundamental principles identified by the AO-OTA association remain ever-relevant. A good reduction of the fracture, stable fixation, maintenance of adequate blood supply, and early mobilization lead to a better healing of the fracture [18].

Another important factor for fracture healing is the patient's comorbidities. Smokers, alcoholics, or patients with diabetes mellitus have a higher risk of non-union [19].

In our opinion, the ideal approach is closed reduction without draining the hematoma, as this method minimizes complications and provides a more favourable environment for healing.

Several limitations are inherent in this study. First, the retrospective design and relatively small patient cohort may limit the generalizability of our findings. Additionally, all clinical data were obtained from a single hospital, which may not reflect outcomes in different settings. Functional outcomes and patient satisfaction were not recorded, and there were variations in the follow-up durations among patients. Furthermore, the surgical procedures were performed by different surgeons, which could introduce variability in surgical technique and outcomes. These factors should be considered when interpreting the results, and further studies with larger, more diverse populations and standardized protocols are needed to validate these findings.

## 5. Conclusion

The management of the third fragment remains a challenge. In our series of patients third fragment characteristics and type of osteosynthesis did not influence the risk of complications. However, the determining factor was found to be the open reduction of the third fragment. Based on our experience, we suggest avoiding the opening of the fracture site and performing closed fracture fixation.

## CRedit authorship contribution statement

E.G., A.C., E.S., N.B., D.A., A.S., M.V.G.: acquisition of data, analysis and interpretation of data, drafting the article.

L.M.: revising article critically for important intellectual content.

G.C.: conception and design of the study, revising article critically for important intellectual content.

All authors read and approved the final manuscript.

## Ethics approval

All procedures performed in studies involving human participants were in accordance with the ethical standards of the institutional and/or national research committee and with the 1964 Helsinki Declaration and its later amendments or comparable ethical standards. The study was approved by the local University-Hospital Human Subject Research Ethics Committee (Comitato Etico Indipendente di Area Vasta Emilia Centro—CE-AVEC 543/2022/Oss/AOUFe 14/09/2022).

## Declaration of Generative AI and AI-assisted technologies in the writing process

No generative AI was used during the creation of this material.

## Funding

None.

## Declaration of competing interest

None.

## References

- [1] Erivan R, Carrie N, Descamps S, Caputo T, Boisgard S, Villatte G. Epidemiology of limb trauma interventions in France: current state and future projections. *Orthop Traumatol Surg Res.* 2024;110(2):103793. <https://doi.org/10.1016/j.otsr.2023>.
- [2] Salminen ST, Pihlajamäki HK, Avikainen VJ, Böstman OM. Population based epidemiologic and morphologic study of femoral shaft fractures. *Clin Orthop Relat Res.* 2000;372:241–9. <https://doi.org/10.1097/00003086-200003000-00026>.
- [3] Mirza A, Ellis T. Initial management of pelvic and femoral fractures in the multiply injured patient. *Crit Care Clin.* 2004;20(1):159–70. [https://doi.org/10.1016/s0749-0704\(03\)00096-4](https://doi.org/10.1016/s0749-0704(03)00096-4).
- [4] Pihlajamäki HK, Salminen ST, Böstman OM. The treatment of nonunions following intramedullary nailing of femoral shaft fractures. *J Orthop Trauma.* 2002;16(6):394–402. <https://doi.org/10.1097/00005131-200207000-00005>.
- [5] Yang S, Yang Y, Huo Y, Yu J, Sheng L, Sun X, et al. Effect of the degree of displacement of the third fragment on healing of femoral shaft fracture treated by intramedullary nailing. *J Orthop Surg Res.* 2022;17:380. <https://doi.org/10.1186/s13018-022-03275-2>.
- [6] Layon D, Morrell AT, Lee C. The flipped third fragment in femoral shaft fractures: a reason for open reduction? *Injury.* 2021;52(3):589–93. <https://doi.org/10.1016/j.injury.2020.09.049>.
- [7] Hamahashi K, Uchiyama Y, Kobayashi Y, Ebihara G, Ukai T, Watanabe M. Clinical outcomes of intramedullary nailing of femoral shaft fractures with third fragments: a retrospective analysis of risk factors for delayed union. *Trauma Surg Acute Care Open.* 2016;4(1):e000203. <https://doi.org/10.1136/tsaco-2018-000203>.

- [8] Persiani P, Noia G, de Cristo C, Graci J, Gurzi MD, Villani C. A study of 44 patients with subtrochanteric fractures treated using long nail and cerclage cables. *Musculoskelet Surg*. 2015;99(3):225–30. <https://doi.org/10.1007/s12306-015-0385-9>. Epub 2015 Oct 29.
- [9] Vicenti G, Carrozzo M, Caiaffa V, Abate A, Solarino G, Bizzoca D, et al. The impact of the third fragment features on the healing of femoral shaft fractures managed with intramedullary nailing: a radiological study. *Int Orthop*. 2019;43(1):193–200. <https://doi.org/10.1007/s00264-018-4214-2>.
- [10] Lee JR, Kim HJ, Lee KB. Effects of third fragment size and displacement on non-union of femoral shaft fractures after locking for intramedullary nailing. *Orthop Traumatol Surg Res*. 2016;102(2):175–81. <https://doi.org/10.1016/j.otsr.2015.11.014>. Epub 2016 Jan 27.
- [11] Louka JG, Seligson D, Vig KS, Zamora R, Zou J, Carlson JB, et al. Femoral shaft fracture with a third fragment treated with an intramedullary nail: Is the displacement of the third fragment predictive of nonunion? *Eur J Orthop Surg Traumatol*. 2024;35(1):27. <https://doi.org/10.1007/s00590-024-04146-8>.
- [12] Hamahashi K, Uchiyama Y, Kobayashi Y, Ebihara G, Ukai T, Watanabe M. Clinical outcomes of intramedullary nailing of femoral shaft fractures with third fragments: a retrospective analysis of risk factors for delayed union. *Trauma Surg Acute Care Open*. 2019;4(1):e000203. <https://doi.org/10.1136/tsaco-2018-000203>.
- [13] Yin Z, Yang S, Yu J, Chen S, Feng T, Huo Y, et al. Analysis of the influence of circumference and displacement of the third fracture fragment on the healing of femoral shaft fractures treated with intramedullary nailing. *Sci Rep*. 2024;14(1):18173. <https://doi.org/10.1038/s41598-024-69137-5>.
- [14] Tsai YH, Wang TK, Lee PY, Chen CH. The butterfly fragment in wedge-shaped femoral shaft fracture: comparison of two different surgical methods. *Orthop Surg*. 2022;14(8):1663–72. <https://doi.org/10.1111/os.13372>.
- [15] Wang TH, Chuang HC, Kuan FC, Hong CK, Yeh ML, Su WR, et al. Role of open cerclage wiring in patients with comminuted fractures of the femoral shaft treated with intramedullary nails. *J Orthop Surg Res* 2021;16:480. <https://doi.org/10.1186/s13018-021-02633-w>.
- [16] Schell H, Duda GN, Peters A, Tsitsilonis S, Johnson KA, Schmidt-Bleek K. The haematoma and its role in bone healing. *J Exp Orthop*. 2017;4(1):5. <https://doi.org/10.1186/s40634-017-0079-3>.
- [17] Schmidt-Bleek K, Schell H, Lienau J, Schulz N, Hoff P, Pfaff M, et al. Initial immune reaction and angiogenesis in bone healing. *J Tissue Eng Regen Med*. 2014;8(2):120–30. <https://doi.org/10.1002/term.1505>.
- [18] Beeharry MW, Ahmad B. Principles of fracture healing and fixation: a literature review. *Cureus*. 2024;16(12):e76250. <https://doi.org/10.7759/cureus.76250>.
- [19] Shapiro JA, Stillwagon MR, Tornetta 3rd P, Seaver TM, Gage M, O'Donnell J, et al. Serology and comorbidities in patients with fracture nonunion: a multicenter evaluation of 640 patients. *J Am Acad Orthop Surg*. 2022;30(18):e1179–87. <https://doi.org/10.5435/JAAOS-D-21-00366>.